

# Ozonated Olive Oil Enhances the Growth of Granulation Tissue in a Mouse Model of Pressure Ulcer

F. Sakazaki,<sup>1</sup> H. Kataoka,<sup>2</sup> T. Okuno,<sup>1</sup> H. Ueno,<sup>1</sup> M. Semma,<sup>2</sup> A. Ichikawa,<sup>2</sup> and K. Nakamuro<sup>1</sup>

<sup>1</sup>Department of Public Health & Preventive Pharmacology, Faculty of Pharmaceutical Sciences, Setsunan University, Osaka, Japan

<sup>2</sup>Laboratory of Health Science, School of Pharmaceutical Sciences, Mukogawa Women's University, Hyogo, Japan

*The curative effect of ozonated olive oil was evaluated using mouse models of cut wounds and pressure ulcers (decubitus or bedsores). Although ozonated olive oil did not significantly accelerate or decelerate wound contraction in either model, some histological modifications were observed. Ozonated olive oil induced blood coagulation in the hypodermis and cell infiltration in the dermis 1 day after its application. Moreover, it enhanced the formation of granulation tissue 10 days after application. These results indicate that ozonated olive oil promotes granulation tissue formation and is effective in the healing of wounds and pressure ulcers.*

**Keywords** Ozone, Medical Applications, Ozonated Olive Oil, Granulation Tissue Formation, Pressure Ulcer, Wound Healing

## INTRODUCTION

Ozonated olive oil is prepared by bubbling ozone gas into olive oil that contains triolein, a trioleoylglycerol as a main constituent. Since three ozone molecules attack the  $-C=C-$  double bonds of the triolein to produce one molecule of triolein triozonide, ozonated olive oil may contain degraded products of triolein triozonide such as aldehydes and fatty acids (Matsumoto, 2001; Nakamuro, 2005; Iwai, 2007). It has been reported that ozonated olive oil can be effective for treating pressure ulcer (decubitus or bedsore) and fistula (Matsumoto, 2001; Sakurai, 2001). For an intractable disease like pressure ulcers that require long-term treatment, inexpensive medications such as ozonated

olive oil are desirable. However, the mechanisms of the curing action of ozonated olive oil for pressure ulcers have not yet been completely elucidated.

Generally, recovery from a cut wound is considered to progress in the following manner. First, in the inflammation period, blood vessels expand and neutrophils and macrophages collect at the wound site where they are recognized as an exudate or pus. Second, in the proliferation period, various growth factors are produced to stimulate the proliferation of fibroblasts and keratinocytes, and a granulation tissue develops (Moriguchi, 2005). Although the appearance of a pressure ulcer differs from that of the cut wound, it is assumed that the healing of both these wounds follow a similar process. The first step of this healing process is called the black period. This is the most severe stage of the pressure ulcer, and the wound is surrounded by necrotic tissue. At the next stage, granulation tissue, which appears red in color, proliferates from the bottom of the wound. In the final step, white epithelial tissue extends from the flanks and covers the wound (Tamura, 2003). To elucidate the pharmacological effects of ozonated olive oil, it is necessary to identify the stage at which ozonated olive oil acts.

We have already reported that ozonated olive oil suppresses lymphocyte mitogenesis and macrophage NO production at low concentrations, and does not induce oxidative stress (Nakamuro, 2005). According to the hypothesized process of wound healing mentioned here, an anti-inflammatory effect of the ozonated olive oil conflicts with the process of wound healing effect. The relationship between the anti-inflammatory effect of ozonated olive oil and the wound healing process should be elucidated. Therefore, we developed mouse models of cut wounds and pressure ulcers and treated the animals with ozonated olive oil to evaluate the role of ozonated olive oil in the healing process.

Received 1/31/2007; Accepted 6/21/2007

Address correspondence to K. Nakamuro, Department of Public Health & Preventive Pharmacology, Faculty of Pharmaceutical Sciences, Setsunan University, 45-1, Nagaotoge-cho, Hirakata, Osaka 573-0101, Japan.  
E-mail: nakamuro@pharm.setsunan.ac.jp

## MATERIALS AND METHODS

### Preparation of Ozonated Olive Oil

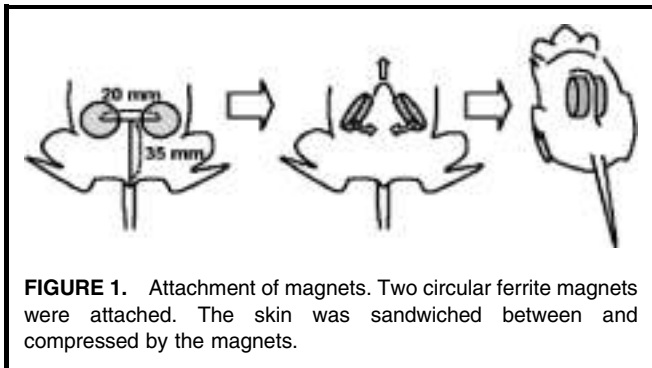
Olive oil (100 ml) (Yamazen Seiyaku, Osaka, Japan) was placed in a 250-ml washing vessel. An ozone/oxygen mixture (20 µg/ml ozone) was passed through the olive oil at 0.5 l/min for 35 h. The ozonated olive oil was stored at 4°C and melted at a room temperature before use.

### Wound Model

A mouse wound model was developed according to the method described by Iba *et al.* (2004). Five-week-old male BALB/c mice (Japan SLC, Shizuoka, Japan) were used. The back hair was shaved under pentobarbital anesthesia, and a circular patch of skin (diameter 7.5 mm) was surgically removed using scissors. The wounds were treated with 15 µl of ozonated or control olive oil. The wound healing state was observed with or without dressing for 21 days. The shapes of the wounds were copied onto a transparent sheet with a pen, the figures were scanned, and the wound areas were analyzed using the Scion Image Beta 4.0.2 software (Scion, Frederick, MD, USA)

### Pressure Ulcer Model

A mouse pressure ulcer model was developed according to the method described by Stadler *et al.* (2004), with a slight modification. Five-week-old male BALB/c mice were used. The hair on the back was shaved using a clipper under pentobarbital anesthesia. The back skin was pinched by 2 circular ferrite magnets of 12-mm diameter, 5-mm thickness, and a magnetic force of 1250 gauss (Seiko Sangyo, Chiba, Japan). The magnets were placed at a distance of 3.5 cm from the root of the tail in the cranial direction, and the distance between the centers of the magnets was 2 cm (Figure 1). The skin was sandwiched between the two magnets and compressed by their magnetic force. The magnets were attached at 9:00 AM, and detached at 5:00 PM for three sequential days. On the following day, 7.5 µl of ozonated olive oil was applied to each side at 9:00 AM. Normal olive oil was applied as a control. Ulcer healing was observed for 21 days.



**FIGURE 1.** Attachment of magnets. Two circular ferrite magnets were attached. The skin was sandwiched between and compressed by the magnets.

### Histological Evaluation

The back skin, including the wound area, was removed surgically, fixed overnight in 0.1 mol/l phosphate buffer (pH 7.4) containing 10% formalin, and embedded in paraffin. Sections on glass slides were dried at 37°C overnight and stained with hematoxylin and eosin for evaluating the general structure or with the Masson trichrome stain for collagen visualization.

## RESULTS

### Effects of Ozonated Olive Oil in the Mouse Wound Model

The mouse models of cut wound were treated with ozonated olive oil, and the rate of wound closure was compared with that of the non-treated mice and the mice treated with control olive oil (Figure 2). With a dressing, suppuration was observed in the control group 4–7 days after application, but it was suppressed in the ozonated olive oil group (Figure 2a). Ozonated olive oil tended to promote wound contraction although the contraction was not statistically significant (Figure 2b). Without a dressing, although the wounds did not suppurate and dried, wound closure was similar to that in the dressing group (Figure 2a, c).

### Effects of Ozonated Olive Oil in the Pressure Ulcer Model

The pressure ulcer mouse models were treated with ozonated olive oil, followed up, and the outcome was compared with that of the non-treated mice and the mice treated with control olive oil (Figure 3). There was no significant difference in the rate of wound closure among the non-treated, control olive oil, and ozonated olive oil groups (data not shown). In the non-treated and control olive oil groups, the skin became solid and dry, and showed internal hemorrhage 2 days after treatment (Figure 3a). A crust was formed at 7–10 days, and after the crust had exfoliated the wounds closed at 14–21 days (Figure 3b). In the ozonated olive oil group, the bleeding was inhibited 2 days after treatment (Figure 3a). A crust was formed at 10 days, similar to that in the control groups, and wound closure followed crust exfoliation (Figure 3b).

### Histological Evaluation of the Pressure Ulcer Model Treated with Ozonated Olive Oil

Histological evaluation was performed in mice at 1 and 10 days after treatment with ozonated olive oil (Figures 4 and 5). In the control groups, 1 day after the treatment, the epidermis was lost, and leakage of red blood cells from the hypodermis and infiltration of white blood cells under the muscoli cutanei were observed (Figure 4a, c). In the ozonated olive oil group, the epidermis was eliminated in a manner similar to that in the control group, and the cell infiltration was enhanced in the

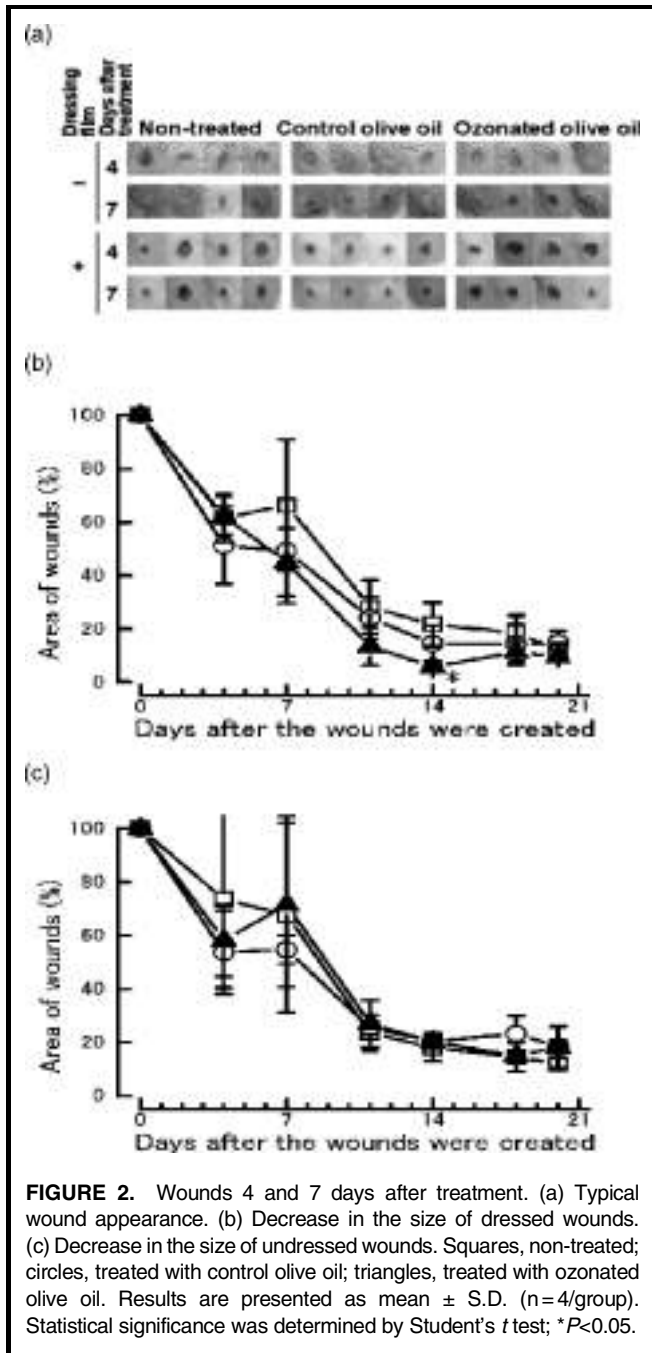
## DISCUSSION

Ozonated olive oil suppressed suppuration and hemorrhage in the wounds and pressure ulcers of mouse models, respectively. This agrees with the results of previous case reports (Matsumoto, 2001; Sakurai, 2001) that present that ozonated olive oil significantly accelerates wound healing. Despite the inhibition of suppuration, there was no delay in wound closure; in fact, it tended to be facilitated. In these experiments we used young and healthy mice that have a high curative ability and the wounds were cured even with no treatment. That may be a reason why ozonated olive oil did not significantly accelerate the wound contraction. These results might suggest that ozonated olive oil accelerates wound healing of mice as well as human.

In the wound healing process, white blood cells infiltrate into the wound area to produce cytokines or growth factors during the inflammation period. These factors activate fibroblasts to proliferate and form granulation tissue (Moriguchi, 2005). This suggests that suppression of inflammation could result in restoration of wound healing. On the other hand, a wound in the oral mucous membrane shows less inflammation, and wound healing occurs earlier than that in the skin (Szpaderska, 2003). This suggests that inflammation can be selectively suppressed when the growth of wound granulation tissue is not suppressed. In our study, ozonated olive oil inhibited suppuration and hemorrhage without delaying wound healing. This demonstrates that ozonated olive oil selectively suppresses one step of the inflammation process and enhances granulation tissue growth.

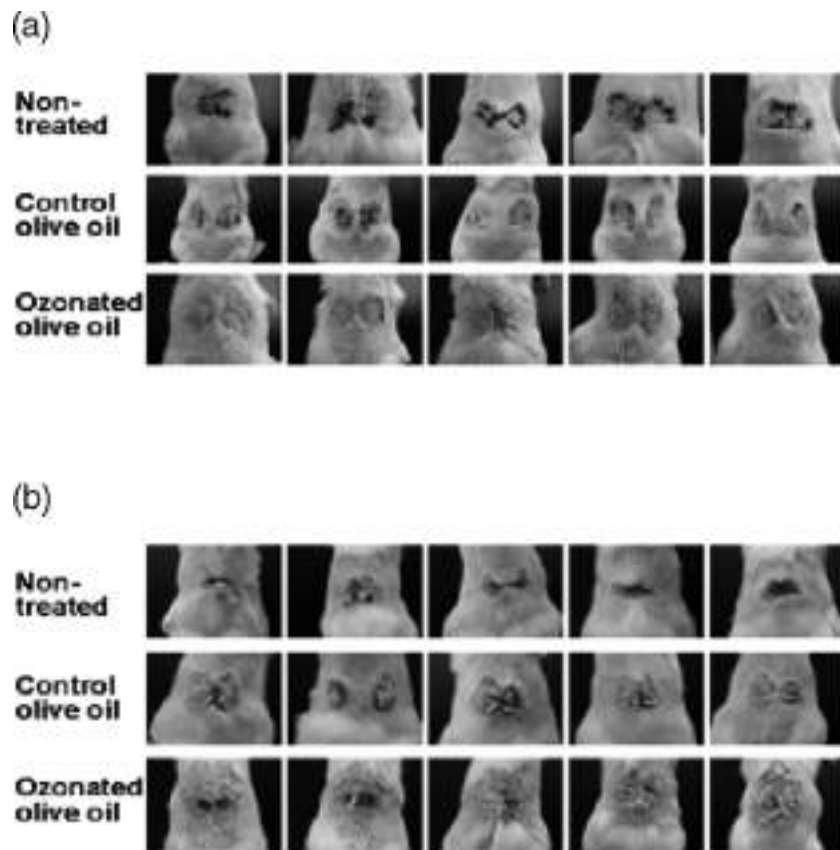
In our histological study, the treatment with ozonated olive oil caused blood coagulation, enhanced cell infiltration, and later promoted the formation of granulation tissue. These results suggest that ozonated olive oil inhibits purulence and hemorrhage, but does not suppress the entire inflammation reaction, and it possibly promotes cell infiltration and induces granulation tissue formation.

Matsuno et al. (1996) reported that the ozone treatment suppressed aggregation of platelets in response to aggregation inducers such as thrombin and collagen. Valacchi et al. (1999), however, reported that ozone treatment itself induced aggregation of platelets and release of transforming growth factor- $\beta$  (TGF- $\beta$ ) in a study of ozone autohemotherapy in which a patient's blood was bubbled with ozone and instilled into his/her vein. In immune response, a cytokine can induce expression of some cytokines while it suppresses expression of other cytokines. TGF- $\beta$  can concern two contrastive effects of ozonated olive oil: The suppression of suppuration and hemorrhage and the enhancement of formation of granulation tissue. The application treatment with ozonated olive oil probably stops bleeding by activating the platelets, which release signaling factors, and these promote granulation tissue formation as part of the healing process of wounds and pressure ulcers.




hypodermis and the dermis around the area where the magnets had been placed (Figure 4b). Moreover, a clot was observed in a hypodermal blood vessel (Figures 4d).


Ten days after treatment with ozonated olive oil, granulation tissue grew from under the muscoli cutanei, and epidermal and dermal tissues extended from the side of the wounded area (Figure 5a, c). Ozonated olive oil did not enhance the extension of the epidermis and dermis, whereas it reinforced the development of granulation tissue (Figure 5b, d). Masson trichrome staining did not demonstrate any significant difference in the dermal collagen synthesis (Figure 5c, d).



**FIGURE 3.** Appearance of pressure ulcers during the healing process. (a) One day after treatment, ozonated olive oil depressed hemorrhage. (b) Ten days after treatment, scab detachment from each mouse differed. The skin shows signs of being regenerated.



**FIGURE 4.** Histological appearance of a pressure ulcer 1 day after treatment. Sections were stained with hematoxylin and eosin. The right half of the pictures shows the wounded area. (a, c) Control olive oil group; (b, d) ozonated olive oil group; (a, b) hypodermis around the wounded area showing infiltration of white blood cells; (c, d) blood vessels in the wounded hypodermis showing red blood cells and a blood clot (arrow).



**FIGURE 5.** Histological appearance of a pressure ulcer 10 days after treatment. The left half of the pictures shows an area of epithelium that has already regenerated (downward arrow). The right half shows granulation tissue (upward arrow). (a, c) Control olive oil group; (b, d) ozonated olive oil group; (a, b) hematoxylin and eosin stain; (c, d) Masson trichrome stain. Typical results from 3 mice are shown.

## CONCLUSIONS

The healing effect of ozonated olive oil was evaluated using mouse models of wounds and pressure ulcers. Ozonated olive oil inhibited suppuration and hemorrhage without delaying wound healing. The histological evaluation of pressure ulcers revealed that ozonated olive oil coagulated blood, enhanced cell infiltration, and later promoted proliferation of granulation tissue. Ozonated olive oil probably activates platelets to aggregate, release signaling factors, and promote formation of granulation tissue. Our results indicate that ozonated olive oil is effective in the healing of wounds and pressure ulcers.

## ACKNOWLEDGMENTS

The authors would like to thank Dr. Yoshinori Iba and Dr. Kiyokazu Ozaki, Setsunan University, Osaka, for their technical advice and Hajime Ezoe for his technical assistance.

## REFERENCES

- Iba, Y., A. Shibata, M. Kato, and T. Masukawa, "Possible Involvement of Mast Cells in Collagen Remodeling in the Late Phase of Cutaneous Wound Healing in Mice", *Int. Immunopharmacol.* 4(14):1873-1880 (2004).
- Iwai, A. and T. Miura, "Crossozonide Included in Ozonated Olive Oil", *The 12<sup>th</sup> Annual Meeting of Japan Research Association for the*

*Medical & Hygienic Use of Ozone*, (15 April 2007) 49-56 (*in Japanese*).

- Matsuno, K., T. Miura, and N. Shinriki, "Effect of Ozone on Platelet Aggregation", *Bulletin of Japan Research Association for the Medical & Hygienic Use of Ozone* 3(4):1-4 (1996) (*in Japanese*).
- Matsumoto, H., S. Sakurai, N. Shinriki, S. Suzuki, and T. Miura, "Therapeutic Effect of Ozonated Olive Oil on Pressure Ulcer, Intractable Fistula, and Intractable Wounds after Surgical Operation", *Bulletin of Japan Research Association for the Medical & Hygienic Use of Ozone* 8(1): 3-8 (2001) (*in Japanese*).
- Moriguchi, T., "Mechanism and Effecting Factors in Healing of Wounds", Ed. K. Harii, and T. Moriguchi, *Treatment of Wounds-Recent Progression*, 2nd ed., Plastic Surgery Advance Series I-3 (Tokyo, Japan: Kokuseido, 2005), pp. 1-13 (*in Japanese*).
- Nakamuro, K., H., Sakazaki, T. Okuno, and H. Ueno, "Suppressive Effects on Immune Cells and Oxidative Cytotoxicity of Ozonated Olive Oil", *International Ozone Association 17th World Congress* (22 Aug 2005) III.1.4: 1-6.
- Sakurai, S., "Results of Clinical Use of Ozonated Olive Oil", *Bulletin of Japan Research Association for the Medical & Hygienic Use of Ozone*, 8(2): 12-19 (2001) (*in Japanese*).
- Stadler, I., R.-Y. Zhang, P. Oskoui, M.S. Whittaker, and R.J. Lanzafame, "Development of a Simple, Non-invasive, Clinically Relevant Model of Pressure Ulcers in the Mouse", *J. Invest. Surg.* 17(4):221-227 (2004)
- Szpadarska, A.M., J.D. Zuckerman, and L.A. DiPietro, "Differential Injury Responses in Oral Mucosal and Cutaneous Wounds", *J. Dent. Res.* 82(8):621-626 (2003).
- Tamura, A., "Local Therapy of Pressure Ulcer", *Visual Dermatol.*, 2:540-545 (2003) (*in Japanese*).
- Valacchi, G. and V. Bocci, "Studies on the Biological Effects of Ozone: 10. Release of Factors from Ozonated Human Platelets", *Mediators Inflamm.* 8(4-5):205-209 (1999).

Copyright of Ozone: Science & Engineering is the property of Taylor & Francis Ltd and its content may not be copied or emailed to multiple sites or posted to a listserv without the copyright holder's express written permission. However, users may print, download, or email articles for individual use.